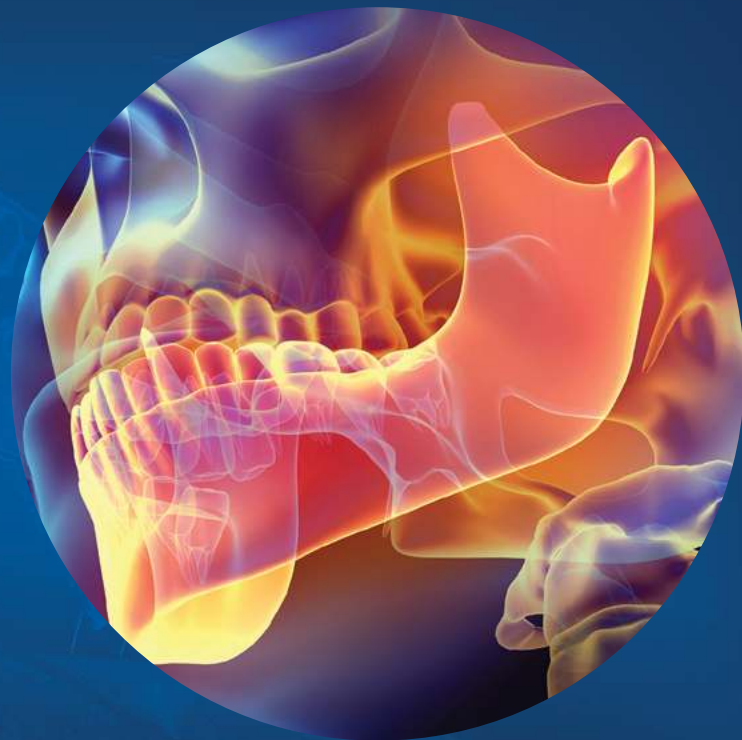


The Impact of Cone Beam Computed Tomography in Endodontics: A New Era in Diagnosis and Treatment Planning



Spring 2018

ENDODONTICS:

Colleagues for Excellence

Published for the Dental Professional Community by the



american association of
endodontists

aae.org/colleagues

ENDODONTICS: Colleagues for Excellence

Clinical examination and diagnostic imaging are essential components of preoperative diagnosis and treatment planning in endodontics. Thorough clinical examination must be performed before considering any radiographic examination. Accurate diagnostic imaging allows the clinician to better visualize the area in question, and supports the clinical diagnosis, treatment plan and outcome assessment. Conventional two-dimensional (2-D) radiographs continue to be the most popular method of imaging today. However, the diagnostic potential of periapical radiographs (PA) is limited. Information may be difficult to interpret, especially when the anatomy and background pattern is complex. These PAs have inherent limitations due to the compressed three-dimensional (3-D) structures in a 2-D image. In addition, interpreting the film-based radiograph or digital image is a somewhat subjective process. Goldman et al. (1) showed that the agreement among six examiners was only 47% when evaluating healing of periapical lesions using 2-D periapical radiographs. In a follow-up study, Goldman et al. (2) also reported that when examiners evaluated the same films at two different times, they only had 19%–80% agreement with their previous interpretations. A recent study evaluated interobserver and intraobserver reliability in detecting periradicular radiolucencies by using a digital radiograph system. Agreement among all six observers for all images was less than 25%, and agreement for five of six observers was approximately 50% (3).

New radiographic imaging systems recently have become available for use in dentistry. Among these new imaging technologies is cone beam computed tomography (CBCT). In 2000, the U.S. Food and Drug Administration approved the first CBCT unit for dental use in the United States. CBCT systems are available in different fields of view (FOV). CBCT with limited FOV, which typically is used for endodontic diagnosis, ranges in diameter from 40–100 mm. Full FOV CBCT, typically used for orthodontics or facial structure imaging ranges from 100–200 mm. The voxel size generally is smaller for the limited version (0.1–0.2 mm vs. 0.3–0.4 mm), thus offering higher resolution and greater utility for endodontic applications. The limited FOV is the most ideal for use in endodontic diagnosis and treatment planning because it is capable of providing images with sufficient spatial resolution at a low radiation dose.

The advent of CBCT can overcome challenges in image interpretation by enabling the clinician to visualize the dentition and the relationship of anatomic structures in three dimensions. CBCT units reconstruct the projection data to provide inter-relational images in three orthogonal planes (axial, sagittal and coronal). This newsletter will review the utilization of CBCT in endodontic diagnosis and management of periapical pathology, diagnosis of pain, cracked teeth and vertical root fractures, nonsurgical and surgical cases, inflammatory resorptive defects and traumatic injuries.

In May 2015 an updated joint position statement of the American Association of Endodontists and the American Academy of Oral and Maxillofacial Radiology was published. The intent of the updated statement is to provide scientifically based guidance to clinicians regarding the use of CBCT in endodontic treatment and reflect new developments since the 2010 statement (4). The updated statement addresses the potential applications and recommendations for use of limited FOV CBCT in different phases of treatment, several of which will be reflected in this newsletter.

Endodontic Diagnosis and Detection of Periapical Lesions

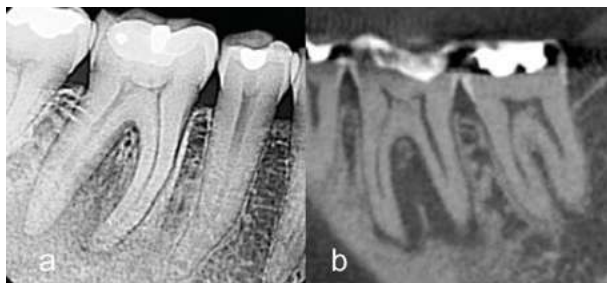

Fig. 1. A patient was referred for evaluation and treatment of tooth #30. Patient presented with pain to percussion and no response to cold testing. Periodontal probing depths were all less than 3mm. Root canal treatment was indicated based on 2-D radiographic findings and clinical tests. 1A is a periapical radiograph of tooth #30. 1B is a CBCT sagittal view of tooth #30. A periapical low-density area involving both mesial and distal roots as well as the furcation was detected.

Endodontic diagnosis is dependent upon evaluation of the patient's chief complaint, medical and dental history, and clinical and radiographic examination. Based on recommendation two of the CBCT position statement, **limited FOV CBCT should be considered the imaging modality of choice for diagnosis in patients who present with contradictory or nonspecific clinical signs and symptoms associated with untreated or previously endodontically treated teeth.**

CBCT imaging has the ability to detect periapical pathology prior to it being apparent on PAs (5) (Figure 1). Clinical studies demonstrate that periapical radiolucency was detected in 20% of cases using radiographs, compared to 48% using CBCT (6). *Ex vivo* studies in which simulated periapical lesions were created showed similar findings (7-8).

Diagnosis of pain is a challenging process for the clinician prior to and after treatment. In challenging diagnostic pain cases, the clinical and radiographic evaluation of the patient may be inconclusive. The ability to determine the etiology of the pain can be attributed to the limitations in both clinical vitality testing and intraoral radiographs to detect the source of the pain.

The Impact of Cone Beam Computed Tomography in Endodontics: A New Era in Diagnosis and Treatment Planning

Persistent pain following root canal treatment also presents a diagnostic challenge to the clinician. Atypical odontalgia (AO) is an example of persistent dentoalveolar pain (9). The diagnostic yield of intraoral radiographs and CBCT was evaluated in the differentiation between patients presenting with apical periodontitis and suspected AO without the evidence of periapical bone destruction. CBCT imaging detected 17% more teeth with apical bone loss (apical periodontitis) than intraoral radiographs (10).

Preoperative Anatomy Assessment

The success of endodontic treatment depends on the identification of all root canal systems so that they can be treated. Recommendation three of the position statement recommends CBCT **for initial treatment of teeth with the potential for extra canals and suspected complex morphology, such as mandibular anterior teeth, and maxillary and mandibular premolars and molars, and dental anomalies (Figure 2).**

The superior ability of CBCT to accurately explore tooth anatomy and identify the prevalence of a second mesiobuccal canal (MB2) in maxillary molars when compared to the gold standard (clinical and histologic sectioning) has been well documented (11-12). CBCT showed higher mean values of specificity and sensitivity when compared to intraoral radiographic assessments in the detection of the MB2 canal (13).

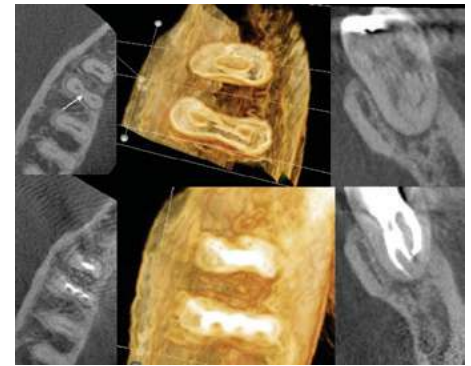


Fig. 2. An example of using CBCT imaging for identification of complex tooth anatomy in a mandibular first molar. CBCT axial and coronal views (top) demonstrating the presence of a middle mesial canal (arrow). One-year recall CBCT axial and coronal views (bottom) demonstrating the obturation of the complex mesial canal anatomy.

Endodontic Diagnosis and Detection of Cracked Teeth and Vertical Root Fractures

2-D radiographs are of limited value for the diagnosis of VRFs and usually only provide indirect evidence of the presence of a VRF. Recommendation six suggests CBCT imaging **if clinical examination and 2-D intraoral radiography are inconclusive in the detection of vertical root fracture.**

Cracked teeth represent a diagnostic and restorative dilemma for both clinicians and patients because of their complicated and vague symptoms and unpredictable prognosis. Treatment plans for cracked teeth depend on the extent and location of the cracks and the severity of the symptoms. In cases of marginal ridge cracks, early detection by CBCT is not possible. Over time, a mesial or distal pattern of bone loss may develop that is indicative of the extent of the longitudinal crack.

Several studies have demonstrated the validity of utilizing CBCT to detect vertical root fractures (VRFs). In a comparative study, the sensitivity and specificity of CBCT and PAs in detecting VRF were evaluated. The sensitivity and specificity were 79.4% and 92.5% respectively for CBCT and 37.1% and 95% respectively for PAs. The same study reported that the specificity of CBCT was reduced in the presence of root canal filling material (14). Higher sensitivity and specificity were observed in a clinical study where the definitive diagnosis of VRF was confirmed at the time of surgery to validate CBCT findings, with sensitivity being 88% and specificity 75% (15). Several case series studies have concluded that CBCT is a useful tool for the diagnosis of VRF. *In vivo* and laboratory studies (16, 17) evaluating CBCT in the detection of VRFs agreed that sensitivity, specificity and accuracy of CBCT generally was higher and more reproducible when compared to traditional radiographs (Figure 3). However, these results should be interpreted with caution because detection of VRFs is dependent on the size of the fracture, presence of radiographic artifacts caused by obturation materials and posts and the spatial resolution of the CBCT. A recent study evaluated the diagnostic ability of a CBCT scan to assess longitudinal root fractures in prosthetically treated teeth (18). The presence of gutta-percha or cast-gold posts reduced the overall sensitivity and specificity. This was attributed to star-shaped streak artifacts that mimic fracture lines in axial views. Another significant problem which can affect the quality and accuracy of CBCT images is the scatter and beam

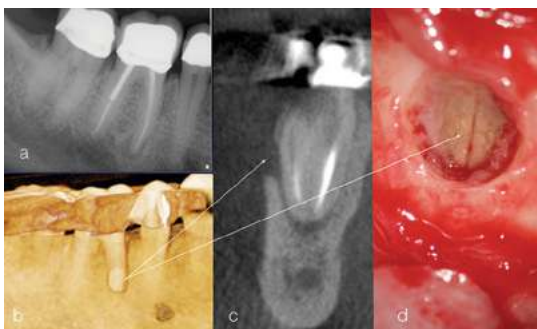


Fig. 3. Example of the sensitivity of CBCT in detecting vertical root fractures. Periapical radiograph of tooth #30 (A). 3-D reconstruction demonstrating the mid-root buccal defect (B) (arrow). Line corresponds to mid-root buccal plate fenestration. Coronal view demonstrating the mid-root buccal bone loss (C) (arrow). Surgical degranulation of the defect confirming the vertical root fracture in the mesial root (D) (arrow).

hardening caused by high density neighboring structures, such as enamel, metal posts and restorations. If a substance

ENDODONTICS: Colleagues for Excellence

that causes this scattering and beam hardening is close to or associated with the tooth being assessed, the overall sensitivity and specificity is dramatically reduced. A thorough dental history, noting classic clinical and radiographic signs and symptoms such as pain, swelling, presence of a sinus tract and/or presence of an isolated deep periodontal pocket can be helpful hints to suggest the presence of a VRF. Radiographically, a combination of periapical and lateral root radiolucency “halo” appearance is valuable information indicating the possible presence of VRFs. Several of the previously mentioned clinical and radiographic elements have to align to establish a presumptive diagnosis of VRF (19); however, dye examination, usually requiring surgical exposure, is still the gold standard for diagnosis of VRF.

Nonsurgical and Surgical Treatment Planning

Diagnostic information directly influences treatment planning and clinical decisions. Accurate data leads to better treatment decisions and potentially more predictable outcomes (21). Recommendations seven and eight from the AAE/AAOMR position statement **identify a variety of circumstances where CBCT imaging may be appropriate in nonsurgical and surgical treatment planning.**

Several studies evaluated the impact of CBCT on diagnosis, clinical decision making and treatment planning (22-24). Ee et al evaluated and compared endodontic treatment planning with CBCT and periapical radiography (22). Thirty endodontic cases completed in a private endodontic practice were randomly selected to be included in the study. Each case was required to have a preoperative digital PA and a CBCT scan. Three Board-certified endodontists reviewed the 30 preoperative PAs. Two weeks later, the CBCT studies were reviewed in random order by the same evaluators. The evaluators were asked to select a preliminary diagnosis and treatment plan based solely on interpretation of the periapical and CBCT images. Diagnosis and treatment planning choices were then compared to determine if there was a change from the PA to the CBCT scan.

Under the conditions of the previous study, CBCT was a more accurate imaging modality for diagnosis of endodontic pathosis when compared to diagnosis using only PAs. An accurate diagnosis was reached in 36.6% to 40% of the cases when using PAs compared to an accurate diagnosis in 76.6% to 83.3% of the cases when using CBCT. The previous

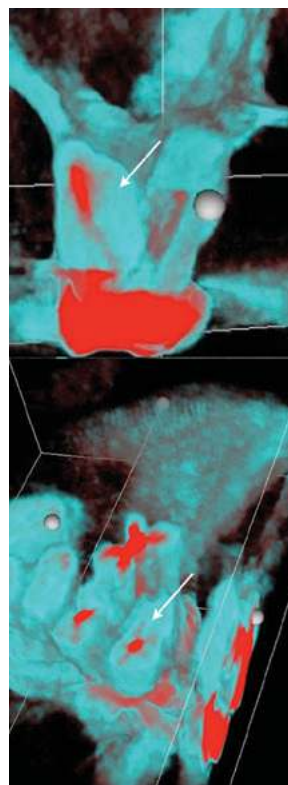


Fig. 4A. 3-D rendering of the MB root of tooth #14 in a coronal view (top) and axial view (bottom) demonstrating the untreated MB2.

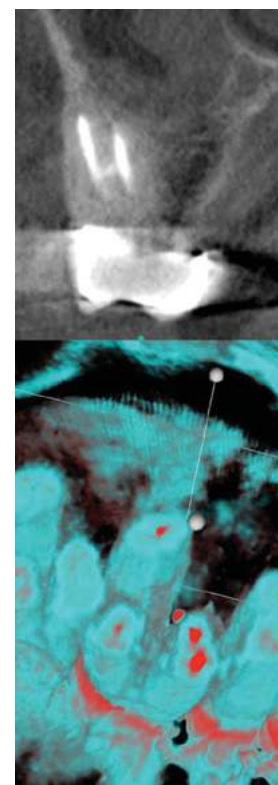


Fig. 4B. Coronal view of two-year recall demonstrating complete healing of the pathology related to MB root after nonsurgical retreatment (top). 3-D rendering axial view demonstrating the obturated MB1 and MB2 (bottom).

study also demonstrated that the treatment plan may be directly influenced by information gained from CBCT studies as the examiners altered their treatment plan after viewing the CBCT scan in 62.2% of the cases overall (range from 56.6% to 66.7%). This high number indicates that CBCT had a significant influence on the examiners' treatment plan. Figures 4A and 4B are examples of the utilization of CBCT imaging in nonsurgical treatment planning.

The use of CBCT has been recommended for treatment planning of endodontic surgery (25-27). CBCT visualization of the true extent of periapical lesions and their proximity to important vital structures and anatomical landmarks is superior to that of PAs. The use of CBCT has enabled the clinician to evaluate the true extent of periapical lesions and their spatial relationship to important anatomical landmarks and vital structures (Figure 5).

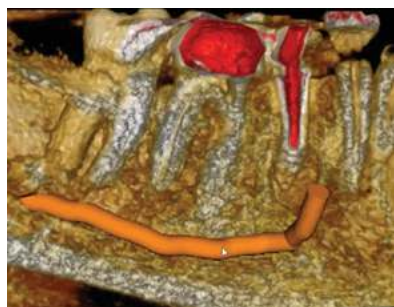

Fig. 5A. 3-D rendering demonstrating the relation of the inferior alveolar nerve (arrow) to the periapical defect and the apex of tooth #29.

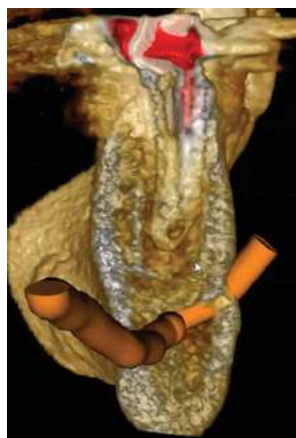

Fig. 5B. A cropped 3-D coronal view rendering demonstrating the mental foramen, bundle and IAN in relation to the base of the periapical defect (arrow). Note the apical root resorption.

Endodontic Diagnosis and Detection of Inflammatory Resorptive Defects

Diagnosis and detection of root resorption is often challenging due to the quiescent nature of onset and varying clinical presentation. Recommendation 12 suggests CBCT imaging **in the localization and differentiation of external and internal resorptive defects and the determination of appropriate treatment and prognosis (Figure 6).**

Definitive diagnosis and treatment planning ultimately is dependent on the radiographic representation of the extent and progression of the disease. 2-D imaging offers a limited diagnostic potential when compared to 3-D imaging (28-29). A 3-D classification for external cervical resorption (ECR) recently published (30) takes into account the ECR lesion height, circumferential spread and proximity to the root canal, thus classifying ECR in three dimensions. This novel and clinically relevant 3-D classification should allow for more effective and accurate communication of ECR lesions between clinicians. It also will allow for an objective assessment of the effect of the ECR on treatment outcomes.

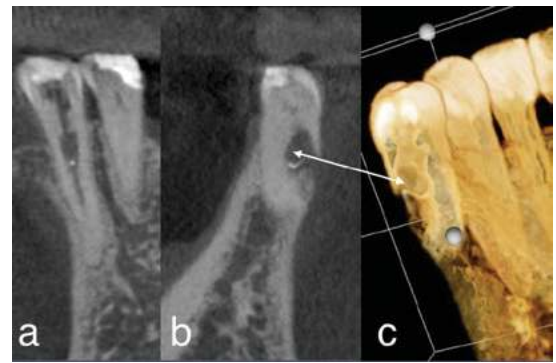

Fig. 6. Example of the utilization of CBCT imaging in diagnosis and treatment planning of inflammatory resorptive defects. Periapical radiograph of tooth #21 (A). The patient was referred for evaluation and treatment of an internal resorptive defect. Coronal view of tooth #21 demonstrating the external/internal resorptive defect (B). 3-D reconstruction of the resorptive defect (B). Note in B and C the perforated root on the buccal aspect (white arrow) rendering tooth #21 nonrestorable. The treatment plan changed after reviewing the CBCT.

Endodontic Diagnosis and Detection of Traumatic Dental Injuries

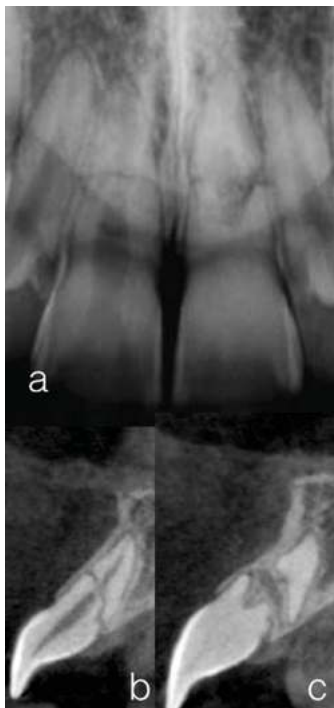

Fig. 7. A 15-year-old patient with history of trauma to the anterior maxilla was referred for consultation for teeth #8 and 9. Tooth #8 had a grade I mobility and tooth #9 had a grade II+ mobility. Periapical radiograph (A) showed mid-root horizontal root fractures teeth #8 and #9. Periodontal probing depths were WNL. Marginal and attached gingiva demonstrated normal color and architecture. Sagittal views of teeth #8 and 9, respectively (B, C). Note the oblique nature of the root fractures and bone fill between the coronal and apical segments in C. Since the patient was asymptomatic and CBCT revealed no periradicular pathosis, a palatal splint was suggested to address the mobility but no endodontic intervention was recommended at the time.

Traumatic dental injuries (TDIs) present a clinical challenge with regard to diagnosis, treatment planning and prognosis. Radiographic assessment is important to identify the location, type and severity of TDIs. According to the 2012 International Association of Dental Traumatology guidelines (31), a series of PAs from different angulations and an occlusal film are recommended for evaluation of TDIs. Unfortunately, 2-D imaging has limitations in the diagnosis and detection of TDI due to projection geometry, magnification, superimposition of anatomic structures, distortion and processing errors. The AAE/AAOMR position statement recommends **CBCT for the diagnosis and management of a variety of traumatic dental injuries, absent other maxillofacial or soft tissue injury that may require other advanced imaging modalities.**

In the diagnosis of horizontal root fractures (HRFs) utilizing 2-D imaging, the fracture line will be evident radiographically only if the central beam is directed within four degrees of the fracture line (32). 2-D imaging has limited accuracy in identifying the location, severity and extent of HRF and could lead to misdiagnosis, improper treatment and an unfavorable outcome. Because of the limitations of intraoral radiography, CBCT is suggested as the preferred imaging modality for diagnosis of HRF (33).

CBCT overcomes several of the limitations of 2-D imaging by providing a considerable amount of 3-D information about the nature and extent of the HRF. The significant difference in the nature of HRF when assessed with 2-D radiographs compared to CBCT has been reported (33). Limited FOV CBCT imaging seems to be generally advantageous in the diagnosis, assessment of prognosis, treatment planning and treatment follow up of HRF cases (Figure 7). In pediatric patients with TDI, it should be noted that children are at greater risk than adults from a given dose of radiation because they are inherently more radiosensitive.

Summary

Several studies evaluated the use of CBCT in endodontics (35-41) and found that its use overcomes many of the limitations of periapical radiography. The increased diagnostic information provided by the CBCT study should result in more accurate diagnosis and improved decision making for the management of complex endodontic problems. It is a desirable addition to the endodontist's armamentarium. The effective radiation dose to patients when using CBCT is higher than conventional 2-D radiography and the benefit to the patient must therefore outweigh any potential risks of the additional radiation exposure, especially in children. Radiation dose should be kept as low as reasonably achievable (42-43). The value of CBCT for endodontic diagnosis and treatment planning should be determined on an individual basis to assure that the benefit: risk assessment supports the use of CBCT. Dentists should utilize the referral to an endodontist as part of the dental team as endodontists use the latest diagnostic imaging, specialty training and techniques to ensure the patient benefits from their diagnostic and treatment planning expertise.

References

1. Goldman M, Pearson AH, Darzenta N. Endodontic success: who's reading the radiograph? *Oral Surg Oral Med Oral Pathol* 1972;33:432-7.
2. Goldman M, Pearson AH, Darzenta N. Reliability of radiographic interpretation. *Oral Surg Oral Med Oral Pathol* 1974;38:287-93.
3. Tewary S, Luzzo J, Hartwell G. Endodontic radiography: Who is reading the digital radiograph? *J Endod* 2011;37:919-21.
4. Joint Position Statement of the American Association of Endodontists and the American Academy of Oral and Maxillofacial Radiology on the Use of Cone Beam Computed Tomography in Endodontics 2015 Update.
5. De Paula-Silva FW, Wu MK, Leonardo MR, da Silva LA, Wesselink PR. Accuracy of periapical radiography and cone-beam computed tomography scans in diagnosing apical periodontitis using histopathological findings as a gold standard. *J Endod* 2009;35:1009-12.
6. Patel S, Wilson R, Dawood A, Mannocci F. The detection of periapical pathosis using periapical radiography and cone beam computed tomography – part 1: preoperative status. *Int Endod J* 2012;8:702-10.
7. Sogur E, Grondahl H, Bakst G, Mert A. Does a combination of two radiographs increase accuracy in detecting acid-induced periapical lesions and does it approach the accuracy of cone-beam computed tomography scanning. *J Endod* 2012;38:131-6.
8. Patel S, Dawood A, Mannocci F, Wilson R, Pitt Ford T. Detection of periapical bone defects in human jaws using cone beam computed tomography and intraoral radiography. *Int Endod J* 2009;42:507-15.
9. Nixdorf D, Moana-Filho E. Persistent dento-alveolar pain disorder (PDAP): Working towards a better understanding. *Rev Pain* 2011;5:18-27.
10. Pigg M, List T, Petersson K, Lindh C, Petersson A. Diagnostic yield of conventional radiographic and cone-beam computed tomographic images in patients with atypical odontalgia. *Int Endod J* 2011;44:1092-1101
11. Blattner TC, Goerge N, Lee CC, Kumar V, Yelton CGJ. Efficacy of CBCT as a modality to accurately identify the presence of second mesiobuccal canals in maxillary first and second molars: a pilot study. *J Endod* 2012;36:867-70.
12. Michetti J, Maret D, Mallet J-P, Diemer F. Validation of cone beam computed tomography as a tool to explore root canal anatomy. *J Endod* 2010;36:1187-90.
13. Vizzotto MB, Silveira PF, Arús NA, Montagner F, Gomes BP, Da Silveira HE. CBCT for the assessment of second mesiobuccal (MB2) canals in maxillary molar teeth: effect of voxel size and presence of root filling. *Int Endod J* 2013;46:870-6.
14. Hassan B, Metska ME, Ozok AR, van der Stelt P, Wesselink PR. Detection of vertical root fractures in endodontically treated teeth by a cone beam computed tomography scan. *J Endod* 2009;35:719-22.
15. Edlund M, Nair MK, Nair UP. Detection of vertical root fractures by using cone-beam computed tomography: a clinical study. *J Endod* 2011;37:768-72.
16. Metska ME, Aartman IH, Wesselink PR, Özok AR. Detection of vertical root fracture in vivo in endodontically treated teeth by cone-beam computed tomography scans. *J Endod* 2012;38:1344-7.
17. Brady E, Mannocci F, Wilson R, Brown J, Patel S. A comparison of CBCT and periapical radiography for the detection of vertical root fractures in non-endodontically treated teeth. *Int Endod J* 2014;47:35-46.
18. Melo SLS, Bortoluzzi EA, Abreu M, Correa LR, Correa M. Diagnostic ability of a cone-beam computed tomography scan to assess longitudinal root fractures in prosthetically treated teeth. *J Endod* 2010;36:1879-82.

The Impact of Cone Beam Computed Tomography in Endodontics: A New Era in Diagnosis and Treatment Planning

19. Tsesis I, Rosen E, Tamse A, Taschieri S, Kfir A. Diagnosis of vertical root fractures in endodontically treated teeth based on clinical and radiographic indices: a systematic review. *J Endod* 2010;36:1455-58.
20. Fayad MI, Ashkenaz PJ, Johnson BR. Different representations of vertical root fractures detected by cone-beam volumetric tomography: a case series report. *J Endod* 2012;10:1435-42.
21. Liang YH, Li G, Wesselink PR, Wu MK. Endodontic outcome predictors identified with periapical radiographs and cone-beam computed tomography scans. *J Endod* 2011;37:326-31.
22. Ee J, Fayad MI, Johnson BR. Comparison of endodontic diagnosis and treatment planning decisions using cone-beam volumetric tomography versus periapical radiography. *J Endod* 2014;40:910-6.
23. Rodríguez G, Abella F, Sindreu F, Patel S, Roig M. Influence of Cone-beam Computed Tomography in Clinical Decision Making among Specialist. *J Endod* 2017;43:194-9.
24. Rodríguez G, Patel S, Sindreu F, Roig M, Abella F. Influence of Cone-beam Computed Tomography on Endodontic Retreatment Strategies among General Dental Practitioners and Endodontists. *J Endod* 2017;43:1433-7.
25. Venskutonis T, Plotino G, Tocci L, Gambarini G, Maminskas J, Juodzbaly G. Periapical and endodontic status scale based on periapical bone lesions and endodontic treatment quality evaluation using cone-beam computed tomography. *J Endod* 2015;41:190-6.
26. Bornstein MM, Lauber R, Pedram Sendi P, and Arx T. Comparison of periapical radiography and limited cone-beam computed tomography in mandibular molars for analysis of anatomical landmarks before apical surgery. *J Endod* 2011;37:151-7.
27. Low KM, Dula K, Bürgin W, Arx T. Comparison of periapical radiography and limited cone-beam tomography in posterior maxillary teeth referred for apical surgery. *J Endod* 2008;34:557-62.
28. Estrela C, Bueno MR, De Alencar AH, Mattar R, Valladares Neto J, Azevedo BC, De Araújo Estrela CR. Method to evaluate inflammatory root resorption by using cone beam computed tomography. *J Endod* 2009;35:1491-7.
29. Durack C, Patel S, Davies J, Wilson R, Mannocci F. Diagnostic accuracy of small volume cone beam computed tomography and intraoral periapical radiography for the detection of simulated external inflammatory root resorption. *Int Endod J* 2011;44:136-47.
30. Patel S, Foschi F, Mannocci F, Patel K. External cervical resorption: a three dimensional classification. *Int Endod J* 2018;51:206-214.
31. Diangelis AJ, Andreasen JO, Ebeleseder KA, et al. International Association of Dental Traumatology guidelines for the management of traumatic dental injuries: 1—fractures and luxations of permanent teeth. *Dent Traumatol* 2012;28:2-12.
32. Rud J, and Omnell KA. Root fracture due to corrosion. Diagnostic aspect. *Scand Journal of Dental Research* 1970;78:397-403.
33. Contemporary management of horizontal root fractures to the permanent dentition: diagnosis--radiologic assessment to include cone-beam computed tomography. *J Endod* 2013 Mar;39:S20-5.
34. Iikubo M, Kobayashi K, Mishima A, et al. Accuracy of intraoral radiography, multidetector helical CT, and limited cone-beam CT for the detection of horizontal tooth root fracture. *Oral Surg Oral Med Oral Pathol Oral Radiol Endod* 2009;108:e70-4.
35. Patel S, Durack C, Abella F, Shemesh H, Roig M, Lemberg K. Cone beam computed tomography in endodontics : a review. *Int Endod J* 2015;48:3-15.
36. Cotton TP, Geisler TM, Holden DT, et al. Endodontic applications of cone-beam volumetric tomography. *J Endod* 2007;33:1121-32.
37. Patel S, Dawood A, Whaites E, Pitt Ford T. New dimensions in endodontic imaging: part 1. Conventional and alternative radiographic systems. *Int Endod J* 2009;42:447-62.
38. Patel, S.: New dimensions in endodontic imaging: part 2. Cone beam computed tomography. *Int Endod J* 2009;42:463-75.
39. Scarfe WC, Farman AG, Sukovic P. Clinical applications of cone-beam computed tomography in dental practice. *J Can Dent Assoc* 2006;72:75-80.
40. Nair MK, Nair UP. Digital and advanced imaging in endodontics: a review. *J Endod* 2007;33:1-6.
41. Setzer FC, Hinckley N, Kohli MR, Karabucak B. A survey of cone-beam computed tomographic use among endodontic practitioners in the United States. *J Endod* 2017;43:699-704
42. Farman AG, Farman TT. A comparison of 18 different x-ray detectors currently used in dentistry. *Oral Surg Oral Med Oral Pathol Oral Radiol Endod* 2005;99:66-71.
43. Farman AG. ALARA still applies. *Oral Surg Oral Med Oral Pathol Oral Radiol Endod* 2005;100:395-7.

Endodontic Case Study

This feature in *Colleagues for Excellence* highlights endodontic treatment that demonstrates the benefits of treatment planning and partnership with an endodontist to improve patient outcomes.

A 14-year-old male was referred for consultation for tooth #31. The panoramic radiograph revealed a radiolucency related to tooth #31 (Figure 1-A). The tooth responded positively to pulp sensitivity tests and periodontal probings were WNL except an 8 mm pocket on the mid-buccal surface. The patient was previously seen by two other dental specialists who both recommended extraction of #31. Figure 1-B (a) Periapical radiograph of tooth #31. (b) Coronal view showing the buccal location of the periapical radiolucency in relation to tooth #31. Notice the apical third of the root is surrounded by bone which explains the positive response to cold and EPT. The lines on the PA correspond to the axial section views in C and D, which demonstrate the origin of the lesion as tooth #32. 3-D reconstruction (e) demonstrates the buccal location of the lesion and explains the isolated deep periodontal probing on the buccal aspect of tooth #31. Tooth #32 was extracted and the lesion was submitted for biopsy. The biopsy result was a dentigerous cyst. Panoramic image is a one-year recall demonstrating complete bony remodeling around #31 (Figure 1-C).

Contributed by Dr. Mohamed I. Fayad

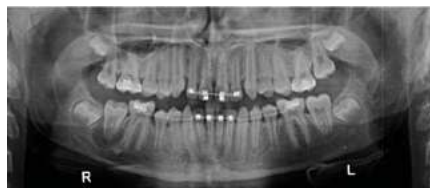

Fig. 1-A.

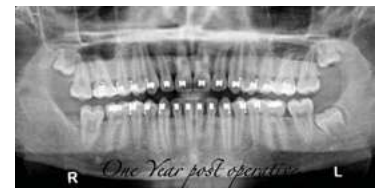

Fig. 1-C.

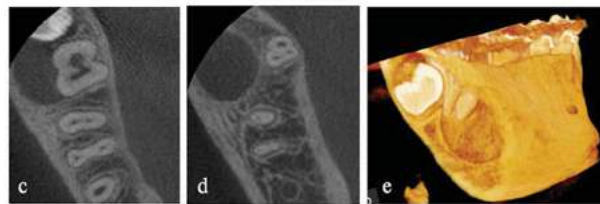
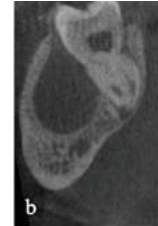
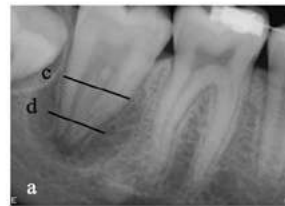

Fig. 1-B.

The AAE wishes to thank Dr. Mohamed I. Fayad for authoring this issue of the newsletter, as well the following article reviewers: Drs. Scott L. Doyle, Steven J. Katz, Keith V. Krell, Garry L. Myers and Jaclyn F. Rivera.

Exclusive Online Bonus Materials: The Impact of Cone Beam Computed Tomography in Endodontics

This issue of the Colleagues newsletter is available online at aae.org/colleagues with the following bonus materials:

- Full-Text Article: Patel K, Mannocci F, Patel S. The Assessment and Management of External Cervical Resorption with Periapical Radiographs and Cone-beam Computed tomography: a clinical study. *J Endod* 2016;42:1435-40.
- AAE/AAOMR Joint Position Statement: Use of Cone Beam Computed Tomography in Endodontics. 2015 Update.
- Full-Text Article: Ee J, Fayad MI, Johnson BR. Comparison of endodontic diagnosis and treatment planning decisions using cone-beam volumetric tomography versus periapical radiography. *J Endod* 2014;40:910-6.



211 E. Chicago Ave., Suite 1100
Chicago, IL 60611-2691
Phone: 800-872-3636 (U.S., Canada, Mexico)
or 312-266-7255
Fax: 866-451-9020 (U.S., Canada, Mexico)
or 312-266-9867
Email: info@aae.org

 [facebook.com/endodontists](https://www.facebook.com/endodontists)

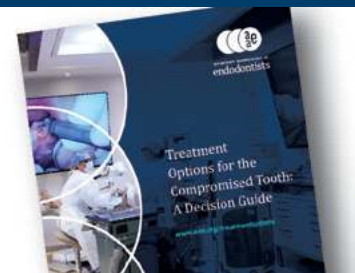 [@SavingYourTeeth](https://twitter.com/SavingYourTeeth)

 [youtube.com/rootcanalspecialists](https://www.youtube.com/rootcanalspecialists)

 www.aae.org

© 2018
American Association of Endodontists (AAE),
All Rights Reserved

**Treatment Options for
the Compromised Tooth:
A Decision Guide**
helps clinicians evaluate
the most challenging cases.
Access this resource at
www.aae.org/treatmentoptions.



Information in this newsletter is designed to aid dentists. Practitioners must use their best professional judgment, taking into account the needs of each individual patient when making diagnosis/treatment plans. The AAE neither expressly nor implicitly warrants against any negative results associated with the application of this information. If you would like more information, consult your endodontic colleague or contact the AAE.

Did you enjoy this issue of Colleagues?

Are there topics you would like to cover in the future? We want to hear from you! Send your comments and questions to the American Association of Endodontists at the address below, and visit the Colleagues online archive at aae.org/colleagues for back issues of the newsletter.