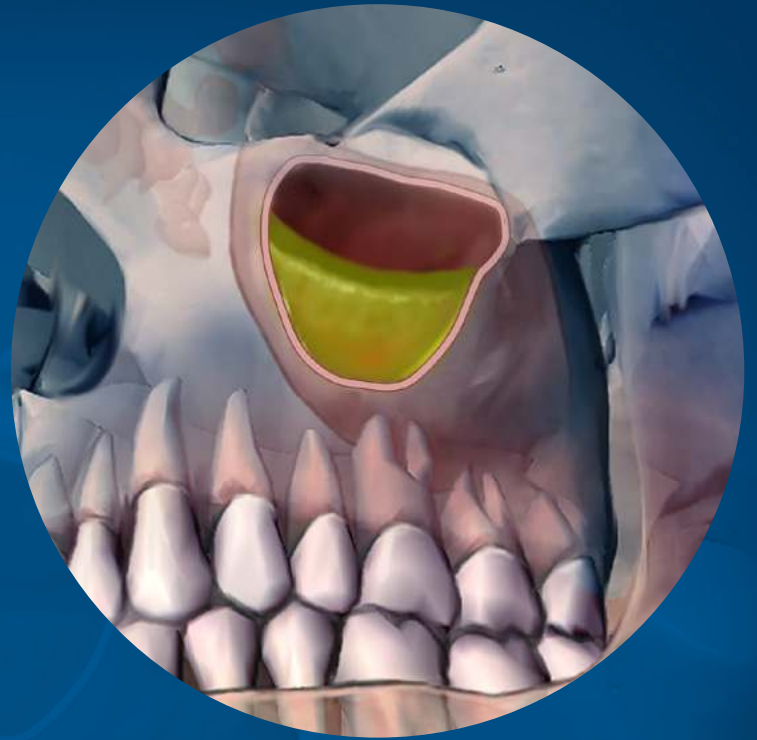


Maxillary Sinusitis of Endodontic Origin

Fall 2018



ENDODONTICS: Colleagues for Excellence

Published for the Dental Professional Community by the



aae.org/colleagues

ENDODONTICS: Colleagues for Excellence

Endodontic infections that develop in maxillary posterior teeth can easily spread into the maxillary sinuses due to their proximity to the antral floor. Typically, only a few millimeters of bone or less separates their root apices from the antrum, and occasionally, no bony partition exists at all, with the roots apices in direct contact with sinus mucosal tissue. (1,2)

The relationship between dental infections and sinus disease is well documented in the dental and medical literature and was first referred to in 1943 as *maxillary sinusitis of dental origin* (MSDO). (3) Numerous investigators since have discovered that this condition, also termed *odontogenic sinusitis*, is a prevalent and common disease process (4-19), with sinus mucosal inflammation seen in 60-80% of patients with infections originating in the maxillary posterior teeth. (4,5,6) The literature also indicates that dental infections may account for more than 40% of maxillary sinusitis cases. (7-10)

Despite its high prevalence, odontogenic sinusitis frequently goes unrecognized by dentists, radiologists, and otolaryngologists - Ear, Nose and Throat (ENT) specialists, with its sequelae often misdiagnosed as sinogenic sinusitis. (10,15,16) Studies have shown that routine general dental examinations using periapical radiographs failed to diagnose odontogenic sinusitis in as high as 86% of the cases. (12,15)

MSDO or odontogenic sinusitis is a broad term used to describe any degree of sinus infection and symptoms, caused by multiple dental etiologies, including periodontal disease, endodontic disease, root fractures, dental implants, dental extractions, oral-antral fistulae, and iatrogenic causes such as extruded dental materials, displaced teeth and foreign bodies. (4,11,17-22) While these can all be odontogenic sources for sinusitis, it is important to distinguish these etiologies from maxillary sinusitis of endodontic origin (MSEO), as they each have a different pathogenesis and require markedly different clinical treatments. MSEO refers specifically to sinusitis caused by endodontic infection, excluding sinusitis secondary to other dental etiologies.

Recognition of MSEO is important as failure to identify and properly manage the endodontic pathosis will result in the persistence of sinus disease and the failure of medical sinus therapies. If left undiagnosed, patients often suffer with chronic sinus infections, ineffectual antibiotic regimens, and may even undergo multiple sinus surgeries, never realizing that an endodontic infection is the source. MSEO also has the potential to advance to more serious or even life-threatening cranio-facial infections. In these severe and rare cases, endodontic infection can spread via the maxillary sinus causing orbital cellulitis, blindness, meningitis, subdural empyema, brain abscess and life-threatening cavernous sinus thrombosis. (6,23-26)

Diagnosis

1. Patient Symptoms

Diagnosing MSEO can be challenging because patients with this condition experience a wide variation of dental and sinonasal symptoms including no symptoms. Typical endodontic symptoms are often not present with MSEO. Thermal pain is usually absent because source teeth for MSEO are most often necrotic or have failing endodontic therapy. Percussion tenderness is typically absent in MSEO because periapical infection is essentially draining into the sinus, eliminating pressure. For this same reason, swelling or intraoral sinus tracts rarely form.

Patients with MSEO will often experience common sinonasal symptoms, which include congestion, rhinorrhea, retrorhinorrhea, facial pain, and foul odor. (27,28) Patients with sinonasal symptoms and without localized dental pain will typically first seek care from their primary care physician or ENT specialist who may misdiagnose and treat MSEO as a primary sinus infection since a dental source is often overlooked during routine ENT examinations. (10,15,28) Current ENT clinical guidelines for the medical management of rhinosinusitis offer no guidance in this area, making no mention of dental infections as a potential cause of sinusitis. (29) For physicians and ENT specialists, findings that should raise the suspicion of MSEO are a history of repeated episodes of unilateral maxillary sinus infections, particularly when associated with a patent sinus ostium or previously unsuccessful sinus surgery. (16) (See Case Feature)

Dentists should always keep sinonasal disease in mind when examining any dental infection in the posterior maxilla and rely on their local endodontists who work closely with ENT specialists to diagnose MSEO and distinguish it from sinogenic sinusitis. Dentists should not attempt to make a final diagnosis of non-odontogenic sinus disease, nor offer treatment that is outside the scope of dental practice.

2. Radiographic Examination

While periapical radiographs are the most widely used imaging modality in endodontics, the posterior maxilla presents significant and unique interpretation challenges when using conventional 2D imaging. (30) Anatomic

structures such as the zygoma, palatal process, maxillary sinus, and buccal cortical plate are often superimposed onto the dental roots, obscuring or concealing periapical infection. Conventional periapical radiographs also do not consistently reveal mucosal thickening or fluid in sinuses, which are of important diagnostic value in MSEO.

Limited field CBCT imaging has been shown to significantly improve the ability to detect odontogenic sources for sinusitis. (31) In a study by Low et al. (32), CBCT revealed 34% more lesions than periapical radiography, as well as significantly more expansion of lesions into the maxillary sinus, mucosal thickening, and untreated canals. Mucosal changes associated with dental infections were found with a prevalence of 77%, compared to only 19% using conventional radiographs.

Throughout the dentition, the dental roots are typically surrounded by alveolar bone, and endodontic disease manifests radiographically as distinct periradicular radiolucent lesions or thickening of the periodontal ligament. The radiographic appearance of endodontic disease on sinus tissues, however, is quite different. (33-36) Two unique radiographic findings associated with periradicular inflammation of the sinus mucoperiosteum are *periapical osteoperiostitis* and *periapical mucositis*. (34)

Periapical Osteoperiostitis (PAO)

The presence of apical periodontitis adjacent to the maxillary sinus cortical floor will often expand the sinus periosteum, displace it upward into the sinus, and subsequently induce a periosteal reaction that continues to deposit a thin layer of new bone on the inner periphery of the periosteum as it expands. This reactive osteogenesis, termed *periapical osteoperiostitis* (PAO), forms a thin, hard-tissue dome on the sinus floor and presents on radiographs and CT images as a radiopaque “halo” appearance. (34) (Fig 1) PAO lesions may or may not be symptomatic and may be accompanied by varying degrees of adjacent mucosal edema and sinus fluid levels.

Periapical Mucositis (PAM)

Symptomatic or asymptomatic apical periodontitis adjacent to the antral mucosa will typically produce a localized mucosal tissue edema termed *periapical mucositis*, which appears radiographically as a mucosal thickening or dome-shaped soft tissue expansion in the floor of the sinus. (34) (Fig 2) Often there is no evident osseous destruction or PAO halo making PAM more difficult to recognize radiographically as having an endodontic source. Mucosal edema on the sinus floor and particularly dome-shaped mucosal swellings directly over dental root apices should raise the suspicion of a dental etiology. Clinicians should be mindful, however, that PAM may have a similar appearance to mucous retention cysts, antral polyps, mucosal thickening caused by periodontal disease, and sinogenic mucosal thickening. As with all endodontic diagnoses, a determination of etiology cannot be made based on radiographic examination alone. Careful endodontic clinical examination of pulpal status is imperative to distinguish PAM from other mucosal abnormalities.

Maxillary Sinusitis of Endodontic Origin Sinus Obstruction

Sinus obstructions cannot be determined with periapical radiographs but are easily seen on sinus CT imaging. Even with CT, however, the obstruction may be difficult to recognize as having an endodontic etiology. (Fig 3) Careful radiographic examination for evidence of PAO is helpful in making this determination but, as seen with PAM lesions, periapical radiolucencies or osseous changes do not always exist. A history of unilateral sinus obstruction, particularly if recurrent and/or associated with a patent ostium is a strong indicator for possible MSEO. Clinical endodontic examination, however, is essential to confirm or rule out a potential endodontic source. (16)

3. Clinical Examination

A thorough clinical endodontic examination is essential for diagnosing or ruling out MSEO. When diagnosing a possible endodontic etiology in patients with sinusitis, the clinician must look carefully for any teeth with pulpal necrosis and evaluate all prior endodontic treatments for possible failure in the suspected quadrant. Because MSEO is a bacterial disease, typically, only teeth with an infected necrotic pulp or failing endodontic treatment will cause significant sinonasal disease or sinonasal symptoms. (36) When examining maxillary posterior teeth with existing root canal treatment, one must carefully examine for any untreated or sub-optimally filled canals, inadequate core restorations, or leaking coronal restorations that may provide evidence of endodontic failure and a bacterial source for MSEO. (37)

Treatment of Maxillary Sinusitis of Endodontic Origin

The objectives for treatment of MSEO are removal of the pathogenic microorganisms, their by-products, and pulpal debris from the infected root canal system that are causing the sinus infection and preventing reinfection. Appropriate

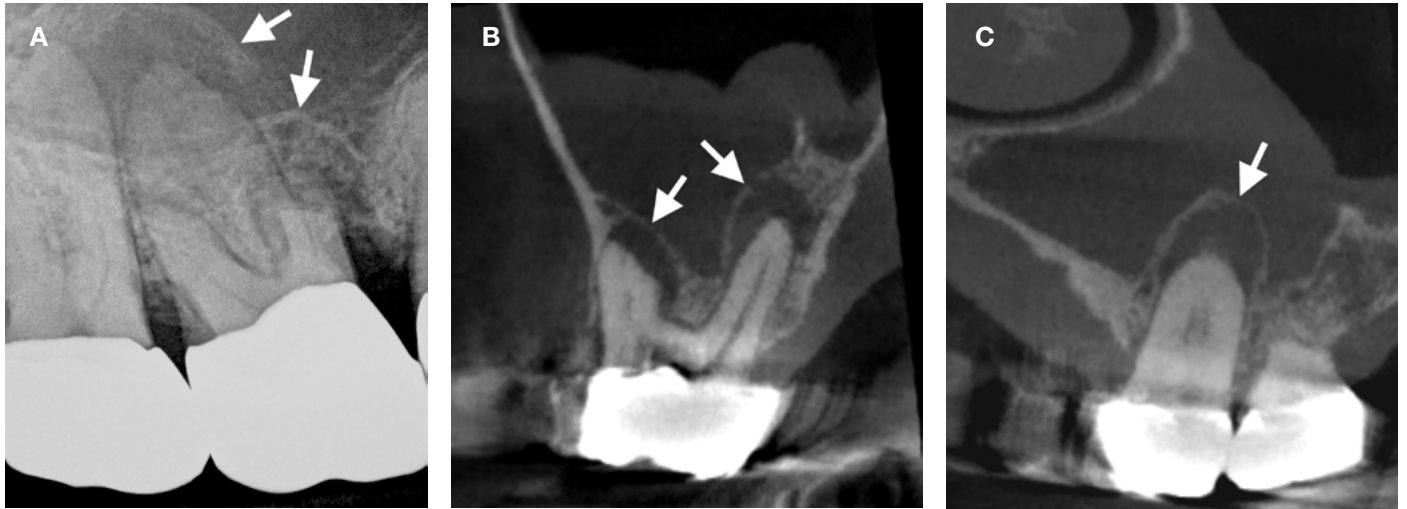


Fig. 1. Periapical osteoperiostitis. **A.** Periapical radiograph of a right maxillary first molar with periapical osteoperiostitis or “halo” lesions over the MB and P root apices. Clinical examination confirmed pulpal necrosis. **B.** Coronal and **C.** sagittal CBCT images of the same necrotic molar displaying periapical osteoperiostitis (arrows) with associated mucosal edema of the right maxillary sinus.

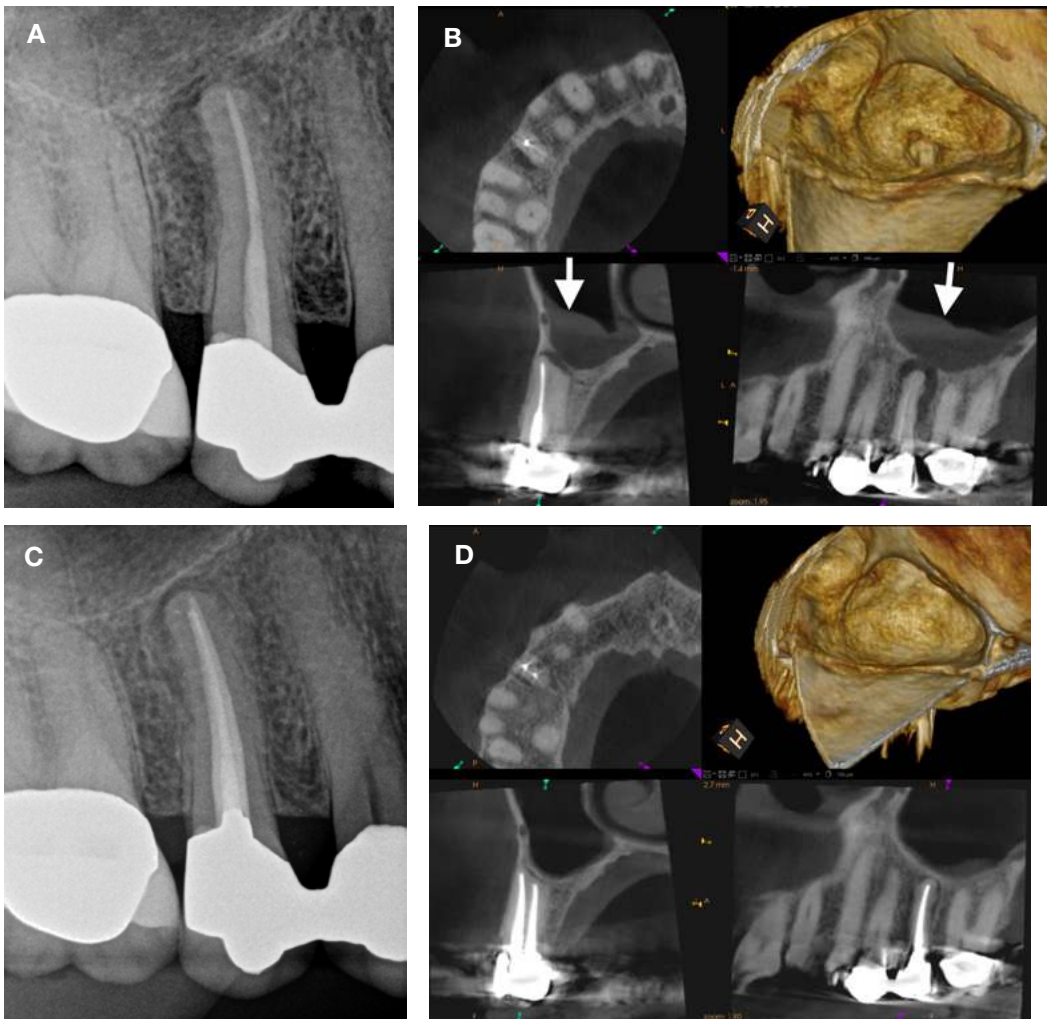


Fig. 2. Periapical mucositis. **A.** Periapical radiograph of a failing root canal therapy of tooth #4. **B.** CBCT reveals an untreated lingual canal tooth #4 with a periapical abscess perforating the sinus floor causing mucosal edema (arrows) in the right maxillary sinus. **C.** Periapical radiograph following endodontic treatment of tooth #4. **D.** 6-month post-operative CBCT showing osseous healing and resolution of the periapical mucositis.

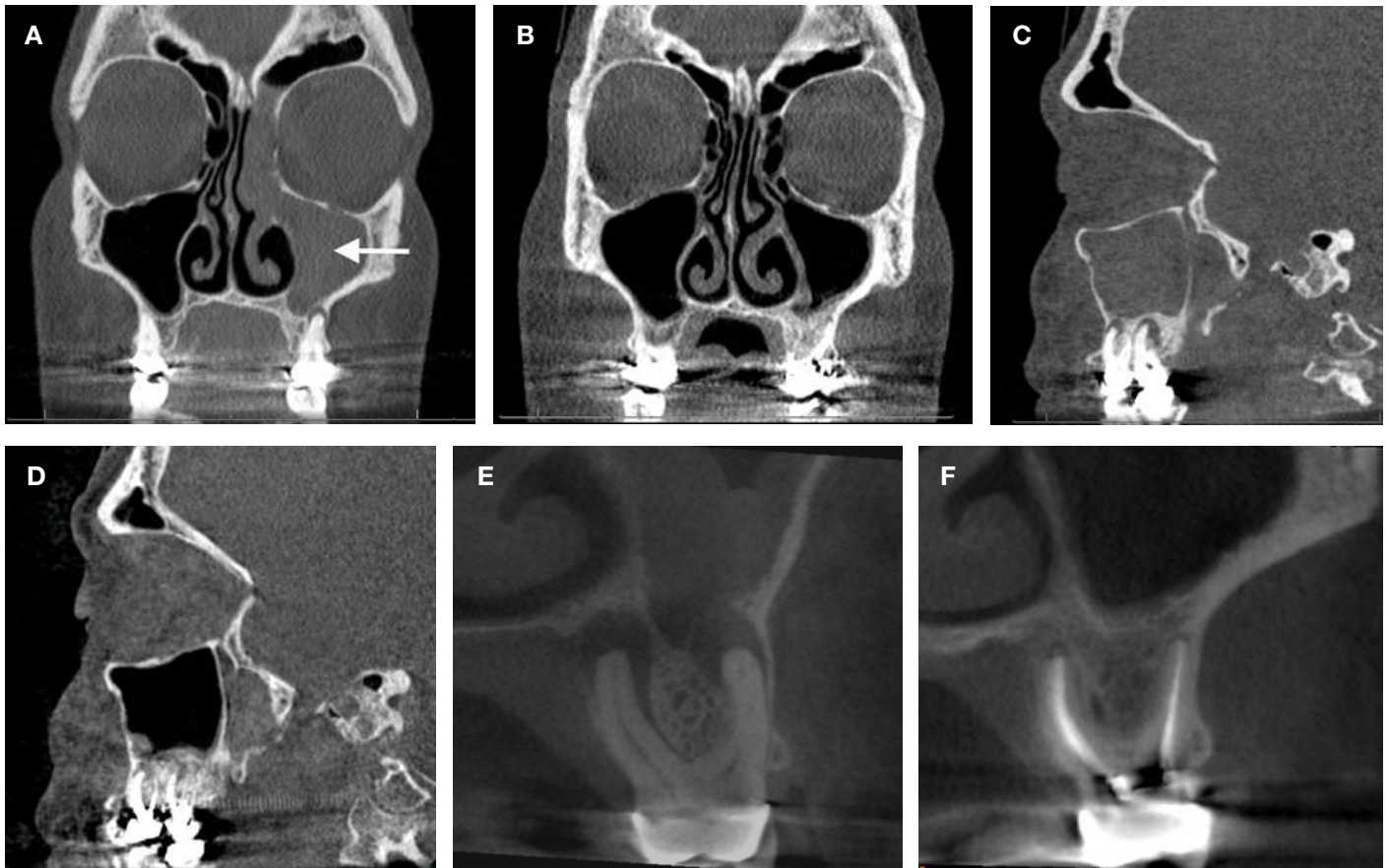

Fig. 3. MSEO sinus obstruction. **A.** Coronal CT image of a fully obstructed left maxillary sinus (arrow). The patient had experienced recurrent left maxillary sinus infections and nasal congestion for several years with no resolution despite multiple antibiotic regimens and adjunctive sinus treatments. **B.** 4-month postoperative coronal CT image showing full resolution of the maxillary rhinosinusitis following endodontic therapy of the necrotic first and second maxillary molars. No other sinus treatment was performed, nor antibiotics administered. **C.** Pre-op and **D.** 4-month postoperative sagittal CT images. **E.** Pre-op Coronal CBCT. **F.** One-year recall coronal CBCT showing osseous healing and full resolution of sinus infection.

treatment options include non-surgical root canal therapy, periradicular surgery when indicated, intentional replantation, or extraction of the infected tooth. Patients should be informed of all treatment options and the prognosis of each option, to include risks of no treatment.

Clinicians performing endodontic treatment in the posterior maxillary dentition should have extensive knowledge of maxillary root canal anatomy, the necessary armamentarium, and requisite clinical skill considering the anatomic complexities and challenges in this region. Maxillary molars typically have the most complex anatomy in the dentition, and inadequate root canal treatment, particularly missed mesio-buccal canal systems, is a common cause of endodontic failure in maxillary molars. (38-42) The close anatomic proximity of maxillary molar root apices to the floor of the maxillary sinus can lead to persistent MSEO if canals are left untreated or root canal failure occurs in these teeth. Endodontists are specialists in managing complex root canal systems and should be heavily relied upon for root canal treatment of maxillary molars.

Use of systemic antibiotics to manage MSEO should follow the guidelines set forth in the *AAE Guidance on the Use of Systemic Antibiotics in Endodontics*. (43) Apart from spreading infections, antibiotic therapy is unwarranted in the treatment of MSEO and ineffective as a definitive solution. While antibiotic therapy may offer temporary relief of symptoms by improving sinus clearing, their sole use is inappropriate without definitive debridement and disinfection of the root canal system.

Similarly, surgical intervention of the maxillary sinus that is focused strictly on removing diseased sinus tissue and establishing drainage is inadequate if the endodontic component is neglected. Although these procedures are performed with the goal of re-establishing sinus aeration and drainage, and may provide relief of some symptoms, it is well documented that neglecting the dental etiology and focusing only on medical and surgical therapies of the

ENDODONTICS: Colleagues for Excellence

ostiomeatal complex (OMC) will not resolve MSEO. (10,44-46)

The dental literature provides numerous case reports showing full resolution of MSEO following endodontic treatment. (4,13,14,15,47-53) It should be noted, however, that endodontic treatment alone may not resolve all cases of MSEO, therefore clinical and radiological follow-up is essential as concomitant management of the associated rhinosinusitis by an ENT specialist may be necessary in some cases. (10,28,50,51,54-57) A collaborative effort and open referral relationship between general dentists, endodontists, and ENT surgeons is essential to achieve the best outcomes for patients with MSEO.

Conclusion

MSEO is fundamentally an endodontic infection manifesting in the maxillary sinus and is a common, yet underappreciated disease process. Symptoms and radiographic signs of MSEO often mimic sinogenic sinusitis leading patients to first seek care from their primary care physician or ENT specialist, whose treatment will not resolve MSEO if the endodontic source is overlooked. MSEO is also frequently overlooked in general dental practice due to a lack of dental symptoms and an obscured or atypical radiographic presentation. The expanded availability of in-office cone-beam computed tomography has increased clinicians' recognition and ability to diagnose MSEO. Clinical endodontic examination, however, remains essential for correct diagnosis. Endodontists are uniquely trained and equipped to diagnose and properly manage endodontic disease that manifests in the maxillary sinus. Solid referral relationships and improved communication between general dentists, endodontic specialists and ENT surgeons are critical to providing appropriate patient care when managing MSEO.

References

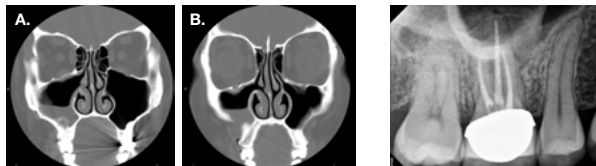1. Eberhardt JA, Torabinejad M, Christiansen EL. A computed tomographic study of the distances between the maxillary sinus floor and the apices of the maxillary posterior teeth. *Oral Surg Oral Med Oral Pathol* 1992;73:345-6.
2. Tian XM, Qian L, Xin XZ, et al. An analysis of the proximity of maxillary posterior teeth to the maxillary sinus using cone-beam computed tomography. *J Endod* 2016;42:371-7.
3. Bauer WH. Maxillary sinusitis of dental origin. *Am J Orthod Oral Surg* 1943;29:133-51.
4. Abrahams JJ, Glassberg RM. Dental disease: a frequently unrecognized cause of maxillary sinus abnormalities? *Am J Roentgenol* 1996;166:1219-23.
5. Mattila K. Roentgenological investigations of the relationship between periapical lesions and conditions of the mucous membrane of the maxillary sinuses. *Acta Odontol Scand* 1965;23:42-6.
6. Obayashi, N., Arijji, Y., Goto, M. et al. Spread of odontogenic infection originating in the maxillary teeth: computerized tomographic assessment. *Oral Surg Oral Med Oral Pathol Oral Radiol Endod* 2004;98:223-31.
7. Maillet M, Bowles WR, McClanahan, SL. Cone-Beam computed tomography evaluation of maxillary sinusitis. *J Endod* 2011;37:753-57.
8. Bomelli SR, Branstetter BF, Ferguson, BF. Frequency of a dental source for acute maxillary sinusitis, *Laryngoscope* 2009; 119(3):580-84.
9. Matsumoto Y, Ikeda T, Yokoi H, et al. Association between odontogenic infections and unilateral sinus opacification. *Auris Nasus Larynx* 2015;42:288-93.
10. Patel NA, Ferguson BJ. Odontogenic sinusitis: an ancient but under-appreciated cause of maxillary sinusitis. *Curr Opin Otolaryngol Head Neck Surg* 2012;20:24-8.
11. Mehra P, Murad H. Maxillary sinus disease of odontogenic origin. *Otolaryngol Clin North Am* 2004;37:347-64.
12. Melen I, Lindahl L, Andreasson L, Rundcrantz H. Chronic maxillary sinusitis. Definition, diagnosis and relation to dental infections and nasal polyposis. *Acta Otolaryngol* 1986;101:320-7.
13. Seldon HS. The interrelationship between the maxillary sinus and endodontics. *Oral Surg Oral Med Oral Pathol Oral Radiol Endod* 1974;38:623-9.
14. Seldon HS. The endo-antral syndrome. *J Endod* 1977;3:462-4.
15. Longhini AB, Ferguson BJ. Clinical aspects of odontogenic maxillary sinusitis: a case series. *Int Forum Allergy Rhinol* 2011;1:409-15.
16. Pokorny A, Tataryn R. Clinical and radiologic findings in a case series of maxillary sinusitis of dental origin. *Int Forum Allergy Rhinol* 2013;3:973-9.
17. Kretzschmar DP, Kretzschmar JL. Rhinosinusitis: Review from a dental perspective. *Oral Surg Oral Med Oral Pathol Oral Radiol Endod* 2003;96:128-35.
18. Legert KG, Zimmerman M, Stierna P. Sinusitis of odontogenic origin: pathophysiological implications of early treatment. *Acta Otolaryngol* 2004;124:655-63.
19. De Lima CO, Devito KL, Vasconcelos LR, et al. Correlation between endodontic infection and periodontal disease and their association with chronic sinusitis: A clinical- tomographic study. *J Endod* 2017;43:1978-83.
20. Zirk M, Dreiseidler T, Pohl M, et al. Odontogenic sinusitis maxillaris: A retrospective study of 121 cases with surgical intervention. *J Craniomaxillofac Surg* 2017;45:520-5.
21. Lechian JR, Filleul O, Costa de Araujo P, et al. Chronic maxillary rhinosinusitis of dental origin: A systematic review of 674 patient cases. *Int J Otolaryngol* 2014;2014:465173. Epub
22. Taschieri S, Torretta S, Corbella S, et al. Pathophysiology of sinusitis of odontogenic origin. *J Investig Clin Dent* 2017;8(2).
23. Eufinger H, Machtens E. Purulent pansinusitis, orbital cellulitis and rhinogenic intracranial complications. *J Cranio Maxillofac Surg* 2001;29:111-7.
24. Wagenmann M, Naclerio RM. Complications of sinusitis. *J Allergy Clin Immunol* 1992;90:552-4.

25. Gold RS, Sager E. Pansinusitis, orbital cellulitis, and blindness as sequelae of delayed treatment of dental abscess. *J Oral Surg* 1974;32:40-3.
26. Park CH, Jee DH, La TY. A case of odontogenic orbital cellulitis causing blindness and severe tension orbit. *J Korean Med Sci* 2013;28:340-3.
27. Williams JW, Simel DL, Roberts L, Samsa GP. Clinical evaluation for sinusitis: making the diagnosis by history and physical evaluation. *Ann Intern Med* 1992;117:705-10.
28. Workman AD, Granquist EJ, Adappa ND. Odontogenic sinusitis: developments in diagnosis, microbiology, and treatment. *Curr Opin Otolaryngol Head Neck Surg* 2018;26:27-33.
29. Rosenfeld RM, Piccirillo JF, Chandrasekhar SS, et al. Clinical practice guideline (update): Adult sinusitis executive summary. *Otolaryngol Head Neck Surg* 2015;152:598-609.
30. Ball RL, Barbizam JV, Cohenca N. Intraoperative endodontic applications of cone-beam computed tomography. *J Endod* 2013;39:548-57.
31. Lofthag-Hansen S, Huuomonen S, Grondahl K, et al. Limited cone-beam CT and intraoral radiography for the diagnosis of periapical pathology. *Oral Surg Oral Med Oral Pathol Oral Radiol Endod* 2007;103:114-9.
32. Low, K.M., Dula, K., Burgin, W., and von Arx, T. Comparison of periapical radiography and limited cone-beam tomography in posterior maxillary teeth referred for apical surgery. *J Endod* 2008;34:557-62.
33. Nunes CA, Guedes OA, Alencar AH, et al. Evaluation of periapical lesions and their association with maxillary sinus abnormalities on cone-beam computed tomographic images. *J Endod* 2016;42:42-6.
34. Worth HM, Stoneman DW. Radiographic interpretation of antral mucosal changes due to localized dental infection. *J Can Dent Assoc* 1972;38:111-6.
35. Tatarzyn RW. Surgical endodontics and the maxillary sinus. In: Torabinejad M, Rubinstein R (eds). *The art and science of contemporary surgical endodontics*. Chicago, IL: Quintessence. 203-22.
36. Tatarzyn RW. Rhinosinusitis and endodontic disease. In: Ingle JI, Bakland LK, Baumgartner JC (eds). *Ingle's Endodontics*, ed 6. Hamilton, ON: BC Decker. 626-37.
37. Gomes AC, Nejaim Y, Silva AIV, et al. Influence of endodontic treatment and coronal restoration on status of periapical tissues: A cone-beam computed tomographic study. *J Endod* 2015;41:1614-8.
38. Wolcott J, Ishley D, Kennedy W, et al. A 5 yr clinical investigation of second mesiobuccal canals in endodontically treated and retreated maxillary molars. *J Endod* 2005;31:262-4.
39. Cleghorn BM, Christie WH, Dong CC. Root and root canal morphology of the human permanent maxillary first molar: a literature review. *J Endod* 2006;32:813-21.
40. Verma P, Love RM. A micro CT study of the mesiobuccal root canal morphology of the maxillary first molar tooth. *Int Endod J* 2011;44:210-7.
41. Degerness RA, Bowles WR. Dimension, anatomy and morphology of the mesiobuccal root canal system in maxillary molars. *J Endod* 2010;36:985-9.
42. Karabucak B, Bunes A, Chehoud C, et al. Prevalence of apical periodontitis in endodontically treated premolars and molars with untreated canal: A cone-beam computed tomography study. *J Endod* 2016;42:538-41.
43. Fouad AF, Byrne BE, Diogenes AR, et al. AAE Guidance on the Use of Systemic Antibiotics in Endodontics. Association of Endodontists Position Statement 2017:1-8.
44. Cartwright S, Hopkins C. Odontogenic sinusitis an underappreciated diagnosis: Our experience. *Clin Otolaryngol* 2016;41:284-5.
45. Kulacz R., Fishman G, Levine H. An unsuccessful sinus surgery caused by dental involvement within the floor of the maxillary sinus. *Op Techniques Otolaryngol Head Neck Surg* 2004;15:2-3.
46. Longhini AB, Branstetter BF, Ferguson BJ. Unrecognized odontogenic maxillary sinusitis: A cause of endoscopic sinus surgery failure. *Am J Rhinol Allergy* 2010;24:296-300.
47. Nenzen B, Welander U. The effect of conservative root canal therapy on local mucosal hyperplasia in the maxillary sinus. *Odontol Revy* 1967;18:295-302.
48. Dodd RB, Dodds RN, Hocomb JB. An endodontically induced maxillary sinusitis. *J Endod* 1984;10:504-6.
49. Bogaerts P, Hanssens JF, Siquet JP. Healing of maxillary sinusitis of odontogenic origin following conservative endodontic retreatment: case reports. *Acta Otorhinolaryngol Belg* 2003;57:91-7.
50. Wang KL, Nichols BG, Poetker DM, Loehrl TA. Odontogenic sinusitis: a case series studying diagnosis and management. *Int Forum Allergy Rhinol* 2015;5:597-601.
51. Tomomatsu N, Uzawa N, Aragaki T, Harada K. Aperture width of the osteomeatal complex as a predictor of successful treatment of odontogenic maxillary sinusitis. *Int J Oral Maxillofac Surg* 2014;43:1386-90.
52. Bedyk-Szeffer M, Lagocka R, Trusewicz M, et al. Perforating internal root resorption repaired with mineral trioxide aggregate caused complete resolution of odontogenic sinus mucositis: A case report. *J Endod* 2015;41:274-8.
53. Nurbakhsh B, Friedman S, Kulkarni GV, et al. Resolution of maxillary sinus mucositis after endodontic treatment of maxillary teeth with apical periodontitis: A cone-beam computed tomographic pilot study. *J Endod* 2011;37:1504-11.
54. Brook I. Microbiology of acute and chronic maxillary sinusitis associated with an odontogenic origin. *Laryngoscope* 2005;115:823-5.
55. Simuntis R, Kubilius R, Vaitkus S. Odontogenic maxillary sinusitis: a review. *Stomatologija* 2014;16:39-43.
56. Saibene AM, Pipolo GC, Lozza P, et al. Redefining boundaries in odontogenic sinusitis: a retrospective evaluation of extramaxillary involvement in 315 patients. *Int Forum Allergy Rhinol* 2014;4:1020-3.
57. Mattos JL, Ferguson BJ, Lee S. Predictive factors in patients undergoing endoscopic sinus surgery for odontogenic sinusitis. *Int Forum Allergy Rhinol* 2016;6:677-700.

Endodontic Case Study

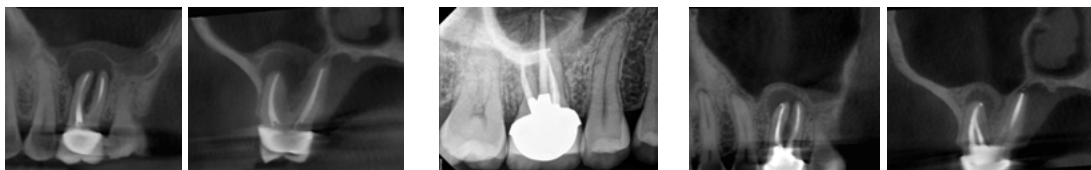This feature in *Colleagues for Excellence* highlights endodontic treatment that demonstrates the benefits of treatment planning and partnership with an endodontist to improve patient outcomes.

This 32-year-old female had been suffering with right maxillary sinus infections for 7 years and had been on multiple rounds of antibiotics and steroids. She had also undergone two sinus surgeries, including a middle meatal antrostomy and later a Caldwell-Luc surgery to remove what the radiologist diagnosed as a “polyp” on the right maxillary sinus floor, but the “polyp” soon reappeared, as did her sinus infection and symptoms. An ENT specialist sent her to her dentist to rule out a dental infection and was told that “the tooth had a root canal treatment done 10 years ago and the X-ray looked good.” She later saw an endodontist, where a careful examination and cone beam CT scan revealed an untreated mesial canal and a large periapical osteoperiostitis lesion over the buccal roots, corresponding to the recurring “polyp” noted by the radiologist. Following endodontic retreatment the patient quickly experienced complete resolution of her longstanding sinus infection and symptoms with no further sinus treatments or use of antibiotics. It is recommended that ENT physicians refer patients that present with recurrent and non-resolving unilateral sinus infections to an endodontist for a thorough endodontic examination to rule out an odontogenic source. It is also recommended that general dentists refer complex maxillary molars to an endodontist for careful diagnosis and treatment to ensure the best possible outcome as these teeth have a high potential to be a source for maxillary sinusitis of endodontic origin.



A. Coronal sinus CT showing right maxillary sinusitis and a periapical osteoperiostitis lesion on the floor the right maxillary sinus. **B.** Coronal CT reveals the the middle-meatal antrostomy and the Caldwell-Luc osteotomy to remove the “polyp.”

Pre-operative periapical radiograph.



Pre-op sagittal and coronal CBCT images showing the periapical osteoperiostitis lesion and mucositis over the buccal root apices of tooth #3.

Post-operative radiograph following retreatment of tooth #3.

Six-month recall CBCT image showing progression of osseous healing, re-establishment of sinus floor, and resolution of the mucositis. Further recall is planned to confirm completion of osseous healing.

The AAE wishes to thank Dr. Roderick W. Tataryn for authoring this issue of the newsletter, as well the following article reviewers: Drs. Mark Desrosiers, Alan Gluskin, Patrick Taylor, Avina Paranjpe, and Ryan Brandtz.

Exclusive Online Bonus Materials: Maxillary Sinusitis of Endodontic Origin

This issue of the *Colleagues* newsletter is available online at aae.org/colleagues with the following bonus material:

- AAE Position Statement: Maxillary Sinusitis of Endodontic Origin. 2018



211 E. Chicago Ave., Suite 1100
Chicago, IL 60611-2691
Phone: 800-872-3636 (U.S., Canada, Mexico)
or 312-266-7255
Fax: 866-451-9020 (U.S., Canada, Mexico)
or 312-266-9867
Email: info@aae.org



[facebook.com/endodontists](https://www.facebook.com/endodontists)



[@SavingYourTeeth](https://twitter.com/SavingYourTeeth)



[youtube.com/rootcanalspecialists](https://www.youtube.com/rootcanalspecialists)



www.aae.org

© 2018
American Association of Endodontists (AAE),
All Rights Reserved

**Treatment Options for
the Compromised Tooth:
A Decision Guide**
helps clinicians evaluate
the most challenging cases.
Access this resource at
www.aae.org/treatmentoptions.



Information in this newsletter is designed to aid dentists. Practitioners must use their best professional judgment, taking into account the needs of each individual patient when making diagnosis/treatment plans. The AAE neither expressly nor implicitly warrants against any negative results associated with the application of this information. If you would like more information, consult your endodontic colleague or contact the AAE.

Did you enjoy this issue of *Colleagues*?

Are there topics you would like to cover in the future? We want to hear from you! Send your comments and questions to the American Association of Endodontists at the address below, and visit the *Colleagues* online archive at aae.org/colleagues for back issues of the newsletter.